

Transmissible Venereal Tumor (TVT) In Male Dog: A Case Report On successful Remission through Chemotherapy

Manjeet Kumar*¹, Rakesh Kumar²

¹Veterinary Officer, Department of Animal Husbandry, Himachal Pradesh (India)

²Assistant Professor, Department of Veterinary Pathology, Dr. GC Negi College of Veterinary & Animal Sciences, CSK HPKV Palampur (India)

ABSTRACT

A 4-years-old intact male dog was presented with the history of penile bleeding and frequent urination. Upon clinical examination, it was observed that the animal has cauliflower like tumorous growths on base of the penis. Transmissible Venereal Tumor (TVT) was confirmed by microscopic examination of an impression smear showing presence of numerous discrete round cells with characteristic cytoplasmic vacuolations. Treatment regimen includes Vincristine sulphate, Liver tonics, and multivitamins. The bleeding from penis and gross tumor lesions completely diminish within 4 weeks.

Keywords: Transmissible Venereal Tumor, penile bleeding, cytoplasmic vacuolations, and Vincristine sulphate.

INTRODUCTION

Canine Transmissible Venereal Tumor (TVT), Also Known As Infectious Sarcoma, Venereal Granuloma, Transmissible Lymphosarcoma, Or Sticker Tumor, Is A Contagious, Transmissible Tumour That Usually Transmitted During Coitus (Tella *Et Al.*, 2004). It Has Been Described As A Benign Reticuloendothelial Tumor Of The Dog Affecting Mainly The External Genitalia And Occasionally The Internal Genitalia Of Dogs (Abedin, 2020). It Has A Worldwide Distribution And The Incidence Is Highest In Tropical And Subtropical Regions (Abeka, 2019). Dogs Of Any Breed, Age Or Sex Are Susceptible But More Common In Young Dogs, Stray Dogs And Sexually Active Dogs At 2-5 Years Of Age (Das And Kumar, 2000). Metastasis Of TVT Is Not Common And Only Occurring In Puppies And Immunocompromised Dogs (Ferreira *Et Al.*, 2000). Macroscopically, TVT Lesions Are Often Friable, Hemorrhagic With Nodular, Granulomatous Or Necrotic Cauliflower Like Masses, Red To Flesh In Colour (Abeka, 2019). TVT Mass Is Usually Located On The Caudal Part Of The Penis In The Male Dog, From The Crura To Bulbis Glandis Or The Area Of The Glans Penis And Occasionally On The Prepuce (Anusha *Et Al.*, 2022). In The Bitch, The Tumorous

Mass Usually Found In The Posterior Part Of The Vagina, Often At The Junction Of The Vestibule And The Vagina (Stockmann *Et Al.*, 2011). Transplantation Occurs When Intact Host Tumor Cells Lose The Expression Of Major Histocompatibility Complex (MHC) Class I And II Molecules, Enabling Transposition Of The Tissue To A Healthy Animal By Contact Between Skin And Damaged Mucosa (Murgia *Et Al.*, 2006). Most Common Symptoms Include Pain And Bleeding From Genitalia. Diagnosis Is Based On The Environmental History, Clinical And Cytological Findings. Biopsy For Histological Examination Is The Most Reliable Method For Diagnosis. Surgical Excision, Radiotherapy, Immunotherapy, Biotherapy, And Chemotherapy Are The Various Therapeutic Approaches For TVT (Pignato *Et Al.*, 2011). Treatment With Antineoplastic Drugs Is Highly Successful, Yielding Complete Remission In Over 90% Of Case Using Intravenous Chemotherapy.

HISTORY AND CLINICAL PARAMETERS

A Male Dog Of 4-Year Age Was Presented With The History Of Swelling At The Base Of Penis, Penile Bleeding And Frequent Urination. The Male Dog Was Restrained In Right Lateral Recumbency And The Prepuce Was Retracted In Order To Exteriorize

Relevant conflicts of interest/financial disclosures: The authors declare that the research was conducted in the absence of any commercial or financial relationships that could be construed as a potential conflict of interest.

Penis Up To The Level Of The Bulbus Glandis. On Clinical Examination, There Was Cauliflower Like Tumorous Growths In The Base Of Penis. There Were No Visible Changes In General Body Condition, Except Bleeding From Penis Along With Sniffing And Licking At Genital Area. Feeding And Water Intake Were Normal. The Rectal Temp (101.5°f), Heart Rate (95/Min) And Respiration Rates (45/Min) Were Within The Normal Range.

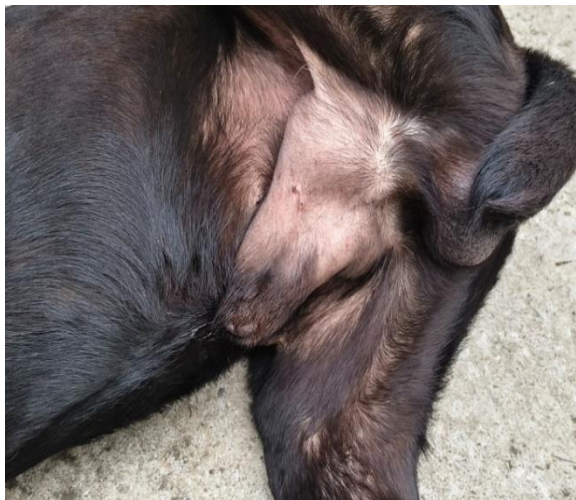
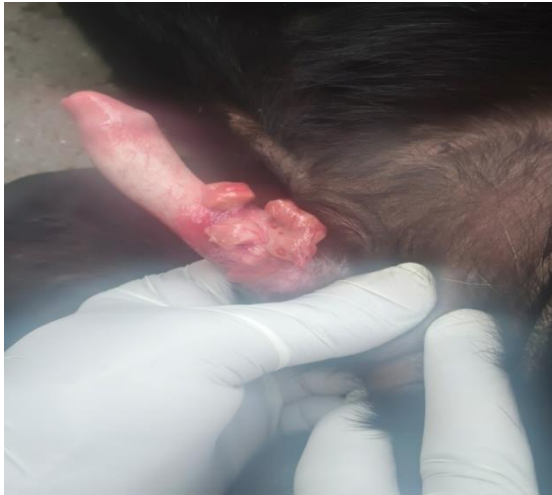
Fig 1: Pictures Depicting Tumor Mass At Base Of Penis.

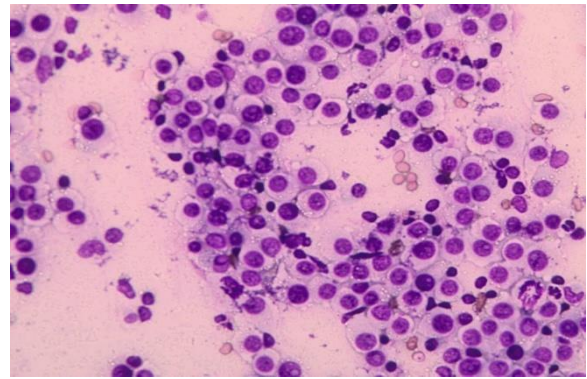
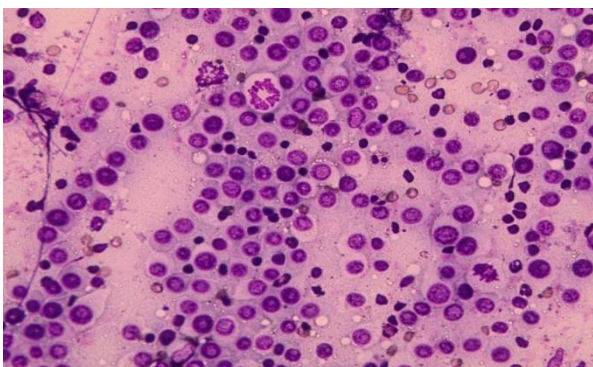


Fig 2: Microscopic Picture (100X) Shows Cytoplasmic Vacuoles And Enlarged Nucleus.

DIAGNOSIS

Clinical Symptoms And Cytological Investigations Were Carried Out For Diagnosis. The Lesions Are Pinkish In Colour, Cauliflower-Like, Multilobulated Masses Present On The Base Of Penis (Anusha *Et Al.*, 2022). Impression Smears From The Tumor Masses Were Collected On Clean, Grease Free Glass Slides And Stained With Giemsa Stain For Cytological Analysis. On Microscopic Examination Of Impression Smears, Multiple Cytoplasmic Vacuoles In The Cytoplasm Of The Cells That Is Suggestive Of TVT (Rai *Et Al.*, 2025). Diagnosis Was Based On Clinical Symptoms And Confirmed Through Cytological Examination Of Impression Smears. Clinical Symptoms And Final Confirmation Through Cytological Examination Are The Standard Diagnostic Procedures For TVT In Dogs (Biswas *Et Al.*, 2024).

TREATMENT PROTOCOL:-

Therapeutic Approaches To Manage TVT, Includes Surgical Excision, Radiotherapy, Immunotherapy, Biotherapy, And Chemotherapy (Pignato *Et Al.*, 2011). Intravenous Administration Of Vincristine Is The Most Effective And Preferred Treatment (Pimentel *Et Al.*, 2025; Rai *Et Al.*, 2025; Biswas *Et Al.*, 2024). It Is Given Weekly For About 4 To 6 Weeks Until The Tumor Resolves. A Full Cure Is Achieved In The Vast Majority Of Dogs. In The Present Study, Intravenous Administration Of Vincristine Sulfate Is Given On Weekly Basis At Dose Rate Of 0.025 Mg/Kg BW, 0.037mg/Kg BW And 0.05mg/Kg BW For 1st, 2nd And 3rd Week Respectively, Diluted In 10 ML Of Normal Saline Resulted In Complete Remission (Kumar *Et Al.*,

2010; Pansawut *Et Al.*, 2012; Rai *Et Al.*, 2025). Other Treatment Includes Inj Avilin 1ml IM (To Check For Any Medication Reactions), Liver Tonic Syrup (Livotas Pet 5ml, Bid, Orally Daily) And Multivitamins (Syrup A To Z 5 Ml Daily). There Were No Local Tissue Irritation Or Extravasation Reactions Observed During Treatment (Pignato *Et Al.*, 2011). Studies Have Reported Complete Recovery Within Two To Eight Doses (Tella *Et Al.*, 2004); However, In Present Case Complete Recovery Occur Within Four Weeks.

RISK FACTORS & PREVENTION

The TVT Is Transplanted From One Dog To The Other By Direct Contact With The Tumor Mass. The Tumor May Also Spread Through Common Social Behavior Such As Sniffing, Licking, Scratching, Or Biting. TVT Is Most Common In Tropical And Subtropical Urban Areas Having Large Populations Of Stray Or Free-Roaming Dogs. It Affects Sexually Intact (Unneutered/Unspayed) Male And Female Dogs At Significantly Higher Rates. The Most Effective Way To Prevent The Disease Is By Doing Sterilization In Stray Dogs And Controlling Their Social Interactions Along With Prompt Therapy Of The Affected Dogs.

CONCLUSION

The canine transmissible venereal tumour (CTVT) is a contagious tumour that is naturally transmitted between dogs by transfer of living cancer cells during coitus. The bleeding from genitalia in dogs along with abnormal tumorous growths should be suspected for TVT. Presence of characteristic cytoplasmic vacuoles in cytological preparations is a pathognomonic confirmatory diagnostic feature for TVT. In present case, chemotherapy with Vincristine sulfate have shown excellent results against TVT, ultimately achieving complete clinical remission. Sterilization in stray dogs and prompt therapy of the affected dogs are the most effective way to prevent this disease in dogs.

REFERENCES

1. Abedin, S.N. 2020. Canine transmissible venereal tumor: A review. *Journal of Entomology and Zoology Studies*, 8(2), pp.596-599.
2. Abeka, Y.T. 2019. Review on canine transmissible venereal tumor (CTVT). *Cancer Therapy & Oncology International Journal*, 14(4), pp.86-94.
3. Anusha, A., Ramana, K.V., Reddy, K.C.S. and Swathi, B. 2022. Studies on transmissible venereal tumour (TVT) in canines. *The Pharma Innovation Journal*, 11(6S), pp.1544-1547.
4. Biswas, N., Singh, K., Kumar, S., Parmar, S., Srivastava, N. and Khan, M.H. 2024. Therapeutics and Management of Persistent Cases of Canine Transmissible Venereal Tumour: An Update. *Animal Reproduction Update*, 4(2).
5. Das, U. and A. Kumar. 2000. Review of canine transmissible venereal sarcoma. *Veterinary Research Communications*, 24: 545-556.
6. Ferreira, A.J., A. Jaggy, A.P. Varejao, M.L. Ferreira, J.M. Correia, J.M. Mulas, O. Almeida, P. Oliveira and J. Prada. 2000. Brain and ocular metastases from a transmissible venereal tumour in a dog. *Journal of Small Animal Practice*, 41: 165-168.
7. Kumar, A., Gupta, G., Malik, H., Vala, J. and Rachna, R. 2010. Regression of transmissible venereal tumor in a dog treated with vincristine sulphate: a case report.
8. Murgia, C., J.K. Pritchard, S.Y. Kim, A. Fassati and R.A. Weiss. 2006. Clonal origin and evolution of a transmissible cancer. *Cell*, 126: 477-487
9. Pansawut, P., Theewasutrakul, P., Techarungchaikul, S., Ponglowhapan, S. and Chatdarong, K., 2012. Treatment of canine transmissible venereal tumor using vincristine sulfate combined with L-asparaginase in clinical vincristine-resistant cases: a case report. *The Thai Journal of Veterinary Medicine*, 42(1), pp.117-122.
10. Pignato JA, Huning PS, Bercht BS, Albuquerque L. 2011. Transmissible venereal tumor in the palpebral conjunctiva of a dog: case report. *Semina Cienc Agrar*. 32(3):1139-44.
11. Pimentel, P.A.B., Giuliano, A., Odatzoglou, P., Ignatenko, N., Wenceslau, R.R., Almeida, I.O., da Silva, P.H.S., Costa, M.D.P. and Horta, R.D.S. 2025. Clinical Guidelines for Canine Transmissible Venereal Tumour Treatment: Systematic Review and Meta-Analysis.

- Veterinary and Comparative Oncology, 23(2), pp.125-140.
12. Rai A, Awasthi A, Kharab A, Saurabh, Jaiswal S. 2025. Transmissible Venereal Tumor (TVT) and its successful treatment in canines. *International Journal of Veterinary Sciences and Animal Husbandry*. 10(10): 401-403
 13. Stockmann, D., F.F. Heitor, L.A. Alexandre, A.L. Rodrigo, C.C. Tereza and C.R.L. Maria. 2011. Canine Transmissible Venereal Tumors: Aspects Related to Program
 14. Tella MA, Ajala OO, Taiwo VO. 2004. Complete regression of transmissible venereal tumor (TVT) in Nigerian mongrel dogs with vincristine sulphate chemotherapy. *African Journal of Biomedical Research*. 7(3):133-138.

HOW TO CITE: Manjeet Kumar*¹, Rakesh Kumar², Transmissible Venereal Tumor (TVT) In Male Dog: A Case Report On successful Remission through Chemotherapy, *Int. J. Sci. R. Tech.*, 2026, 3 (6), 453-456. <https://doi.org/10.5281/zenodo.20566928>